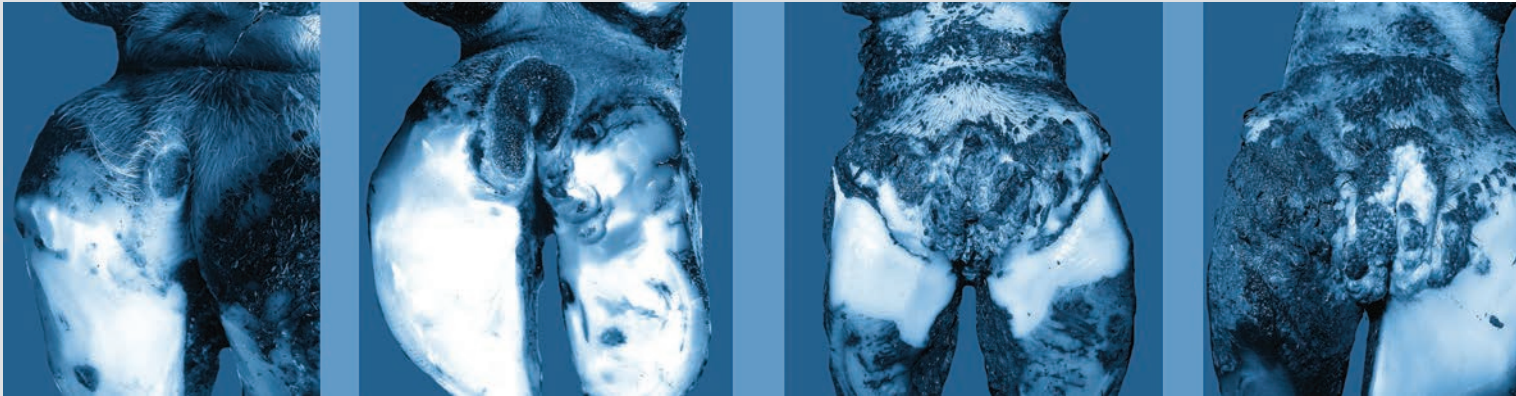


# ICAR Claw Health Atlas - Appendix 1

## Digital Dermatitis Stages (M-stages)



by J. Kofler, A. Fiedler, N. Charfeddine, N. Capion, T. Fjeldaas,  
G. Cramer, N.J. Bell, K.E. Müller, A.-M. Christen, G. Thomas,  
B. Heringstad, K.F. Stock, M. Holzhauser, J.M. Nieto,  
C. Egger-Danner and D. Döpfer

**January 2020**



# Publishing Information

**Title of the series:** ICAR Technical Series

**Title of the issue:** ICAR Claw Health Atlas - Appendix 1: Digital Dermatitis Stages (M-stages)

**Editors:** ICAR Working Group on Functional Traits (ICAR WGFT) and international claw health experts

**Coordination of work:** Christa Egger-Danner

**Citation:** Kofler J., Fiedler A., Charfeddine N., Capion N., Fjeldaas T., Cramer G., Bell N.J., Müller K.E., Christen A.-M., Thomas G., Heringstad B., Stock K.F., Holzhauser M., Nieto J.M., Egger-Danner C. and Döpfer D. (2019). ICAR Claw Health Atlas - Appendix 1: Digital Dermatitis Stages (M-stages).

<http://www.icar.org/Documents/ICAR-Claw-Health-Atlas-Appendix-1-DD-stages-M-stages.pdf>

## **Authors and contributors**

### *Austria:*

Christa Egger-Danner, Zucht Data EDV-Dienstleistungen GmbH, Vienna;

Johann Kofler, University Clinic for Ruminants, University of Veterinary Medicine, Vienna

### *Canada:*

Anne-Marie Christen, Valacta, Québec

### *Denmark:*

Nynne Capion, Department of Large Animal Sciences, University of Copenhagen, Copenhagen

### *France:*

Gilles Thomas, Institut de l'Élevage, Paris



*Germany:*

Andrea Fiedler, Hoof Health Practice Drs. Fiedler, Grimm & Kröger, Munich;  
Kerstin Müller, Veterinary Medicine Faculty, Freie Universität, Berlin;  
Kathrin Friederike Stock, VIT/Vereinigte Informationssysteme Tierhaltung w.V., Verden

*Norway:*

Bjorg Heringstad, Department of Animal and Aquacultural Sciences, Norwegian Univ. of Life Sciences, Ås;  
Terje Fjeldaas, Norwegian University of Life Sciences, Oslo

*Spain:*

Noureddine Charfeddine, Conafe, Madrid  
Nieto Jose Maria, Claw Health Care Service SERAGRO, A Coruña

*The Netherlands:*

Menno Holzhauer, GD Animal Health, Deventer

*United Kingdom:*

Nick J. Bell, Wimborne, Dorset

*United States of America:*

Dörte Döpfer, Food Animal Production Medicine, School of Vet. Medicine, Univ. of Wisconsin, Madison;  
Gerard Cramer, College of Veterinary Medicine, University of Minnesota, St. Paul

**Publisher:** ICAR, Via Savoia 78, Scala A, Int. 3, 00191, Rome, Italy; Tel: +39 06 85 237 1; Email: [icar@icar.org](mailto:icar@icar.org)

**Copyright by:** ICAR, Via Savoia 78, Scala A, Int. 3, 00191, Rome, Italy

**ISSN:** 92-95014-14-6

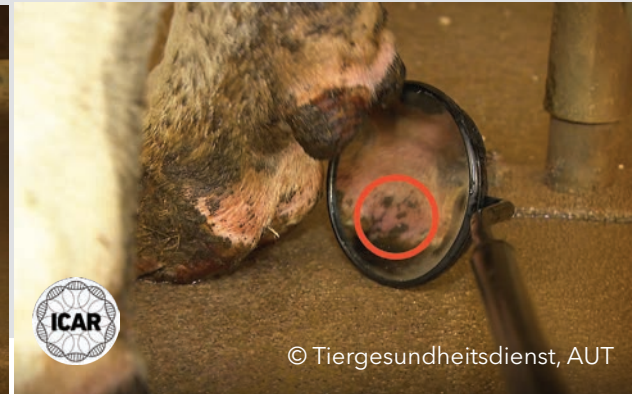**ISBN:** 92-95014-21-9

**Edition:** First edition, January 2020



# Table of contents

M-stages scoring system for digital dermatitis lesions	5
DD cycle or dynamics of transition of DD stages	8
Images at different stages	10
List of image contributors	39



# M-stages scoring system for digital dermatitis lesions

The M-stages scoring system was developed by Dörte Döpfer (University of Wisconsin, Madison School of Veterinary Medicine, USA). The M- (Mortellaro) stages scoring system classifies cows showing signs of digital dermatitis (DD) into one of five disease stages: **M1, M2, M3, M4** and **M4.1**. In addition, healthy digital skin is classified as **M0**.

The M-stages scoring system is a highly effective way to diagnose and monitor digital dermatitis. Depicting the life cycle of the disease, M-scoring enables a dairy operation to improve its hoof health program and quantify economic losses associated with the serious impact of this disease on animal welfare. This classification system helps farmers, hoof trimmers and veterinarians gauge the effectiveness of current treatment and prevention protocols, which, in turn, can help a farm break the vicious cycle of digital dermatitis. Transitions between M-stages of DD can occur within 10 days, but these intervals can vary between individual cows depending on genetic susceptibility, infectious pressure and the impact of risk factors. Recording the current DD status is vital for choosing the correct course of therapeutic and/or preventive action for the individual animals and at the population level.

The M-stages scoring system recognizes five stages of DD and the healthy digital skin (Döpfer *et al.* 1997; Berry *et al.* 2012):

**M0 stage: Normal, healthy skin without signs of DD.** An M0 stage may reflect a healthy skin with no visible evidence of previous DD lesions. However, if no outer signs for DD are visible, this is no guarantee that there has never been a (clinically) healed DD lesion before. On farms with endemic DD, it is recommended to record all M-stages, including the M0 stage.

**M1 stage: Early stage of DD; a small, focal active, red-grey, circumscribed lesion less than 2 cm in diameter located in the skin of the interdigital cleft (plantar or dorsal) or in any other location of the skin around the claw or on the exposed corium of claw horn lesions.** These skin defects come and go generally within 10-day intervals. Detection of M1 stages in the milking parlor can be facilitated by cleaning the area and the additional use of a swiveling mirror and a powerful headlamp. Detection of M1 stages on the cow restrained in the hoof-trimming crush can be supported by using spreader forceps.



**M2 stage: Acute, bright red or red-gray ulcerative lesion a minimum of 2 cm in diameter and commonly observed on the skin of the plantar or dorsal interdigital cleft, along the coronary band, as well as around the dew claws and on interdigital hyperplasia. The M2 lesions are commonly sensitive to the touch, eliciting signs of pain and discomfort in affected cattle upon pressure applied to the wound. M2 lesions exude a typical DD-associated pungent odour.**

Furthermore, M2 stages can be observed in white-line-infections, sole ulcers, bulb ulcers, toe ulcers, toe necrosis and axial and abaxial horn fissures (all of them showing an exposed and infected corium). In these cases, they are called 'digital dermatitis-associated' claw horn lesions (previously known as 'non-healing' claw horn lesions) (see Appendix 2).

**M3 stage: Healing, painless lesion observed after topical treatment covered with firm, brown/gray/green-blue or black scab material.** The color of the scab depends on the applied topical medication.

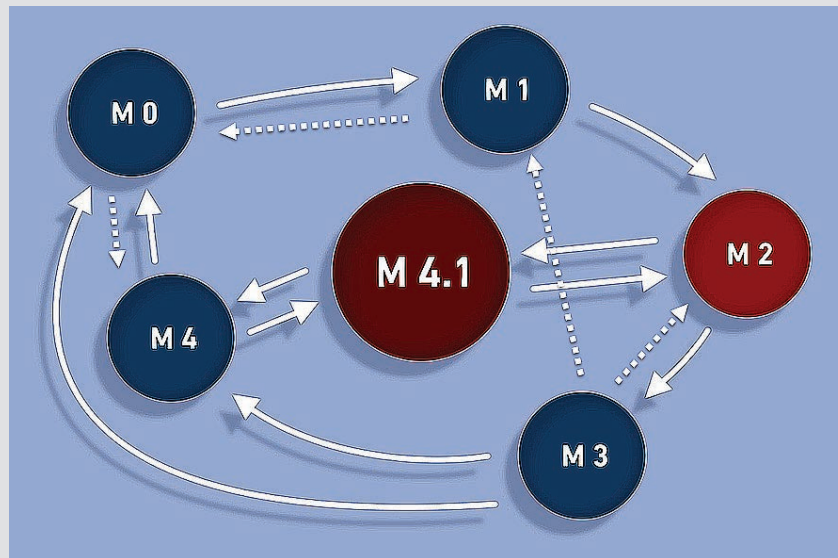
**M4 stage: Chronic stage of DD including lesions of various sizes characterized by a non-painful, clearly circumscribed dys- and hyperkeratosis or irregular proliferative overgrowths ('wart-like') of brown-gray color.** Proliferative stages of DD may be characterized by filamentous, scab-like or mass proliferations.

**M4.1 stage: Chronic M4 stage and new M1 lesion developing within the perimeter of the chronic dys- and hyperkeratotic and/or proliferative M4 lesion.**

### References

- Berry SL, Read DH, Famula TR, Mongini A, Döpfer D (2012): Long-term observations on the dynamics of bovine digital dermatitis lesions on a California dairy after topical treatment with lincomycin hydrochloride. *Vet J.* 193: 654-658.
- Döpfer D, Koopmans A, Meijer FA *et al.* (1997): Histological and bacteriological evaluation of digital dermatitis in cattle, with special reference to spirochaetes and *Campylobacter faecalis*. *Vet. Rec.* 140: 620-623.





DD cycle/Transition of DD stages (modified November 2019)

Source of the idea: D. Döpfer, Cattle Lameness 2013

Source of the layout: Tutorial video of TGD Tirol/Austria on digital dermatitis: <http://www.t-tgd.at/interessantes/film-mortellaro-krankheit>

**DD cycle or dynamics of transition of DD stages:  
Break the cycle - essential strategy in the prevention of any new DD stages  
and/or the prevention of new and painful ulcerative M2 stages**

**M0** indicates the normal, healthy skin without any visible signs of DD: an M0 stage may reflect a healthy skin without any evidence of a previous DD-lesion, but it can indicate also a (clinically) healed DD lesion that shows no more signs of DD when inspected macroscopically.

After the onset of the local skin infection with DD-associated *Treponema spp.* and under the impact of risk factors, the **M1 stage** (early stage) develops. The M1 stage may develop into the acute, ulcerative and painful M2 lesion or return to M0.

Some animals with M1 stages never develop **M2 stages** or they are recorded as M4 stages without ever having had records of an M2 lesion. Accumulation of high numbers of M2 lesions in many cows within a herd increases the infectious pressure of DD to the point of starting an outbreak. Transition from an M1 into an M4 lesion does not always go through an observed M2 stage.





After effective topical treatment of an acute **M2 lesion**, an **M3 stage** develops, and thereafter the course of DD continues most commonly by the development of **M4 lesions**. Transition into M0 stages is extremely rare, but M3 lesions can also develop directly into M1 lesions and thereafter into new M2 lesions. Repeated cases of M2 lesions often do not show improvement after topical treatment and recurrent M2 lesions are common in these cattle.

**M4 stages** will most often transition into the **M4.1** stages while transition into M0 stages is rare. **M4 and M4.1 stages are the reservoir of disease** that harbor encysted *Treponema spp.* deep in the skin.

**M4.1 stages** may return to M4 stages or they may develop into recurrent M2 stages, which closes the DD cycle.

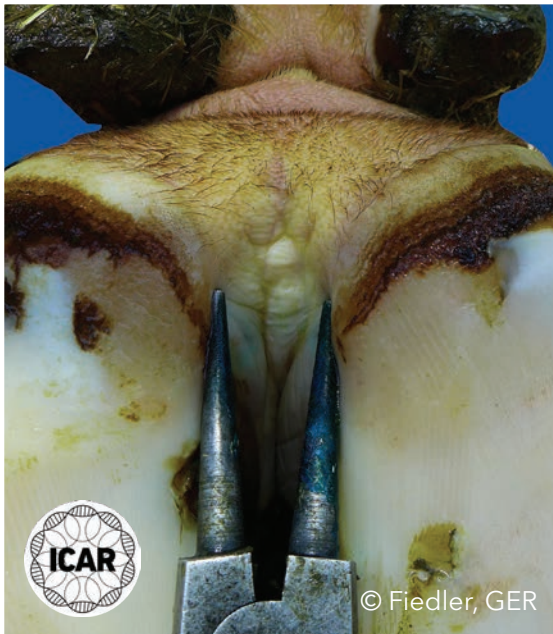**It is recommended to detect M2 (acute) stages early in the course of disease - before signs of chronicity, such as dyskeratosis and proliferation develop - to maximize the effect of treatment.**

**Cattle with M1, M4 and M4.1 stages should be identified by regular checks in the milking parlor or by pen-walks so that preventive measures (hoof bathing) can be applied before a new active and painful M2 stage develops.**



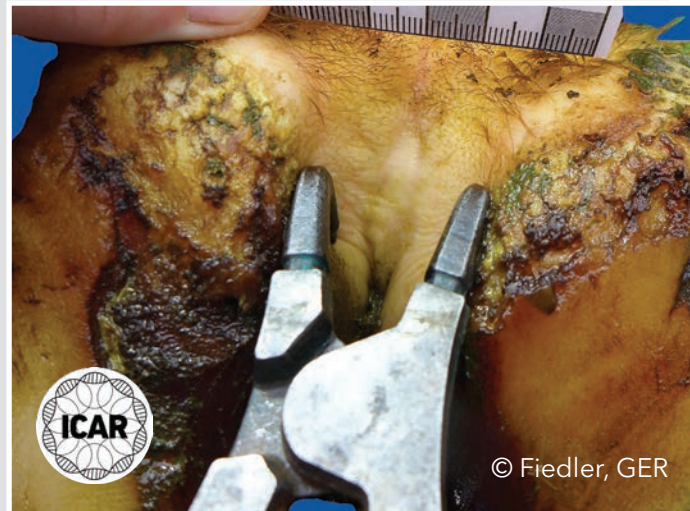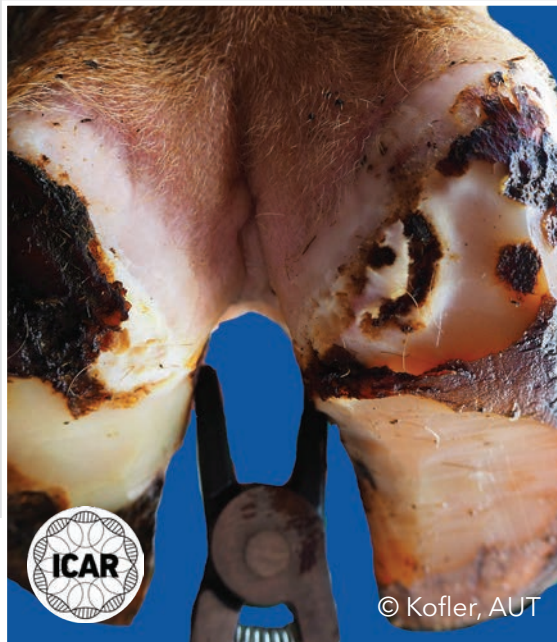## M0 stage

Normal, healthy skin with no visible signs of DD infection or other skin lesions.



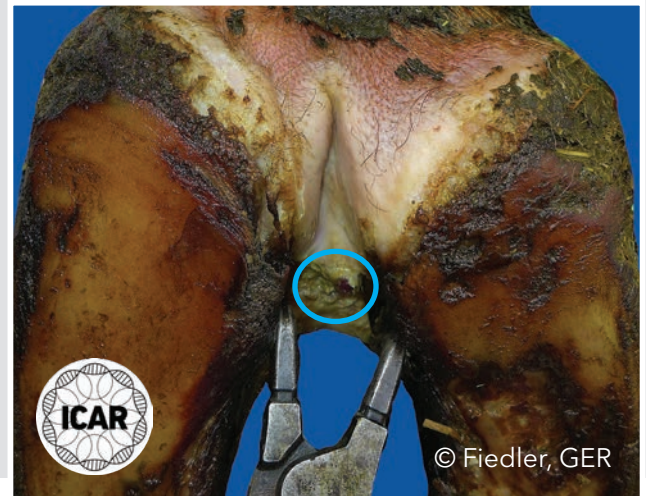
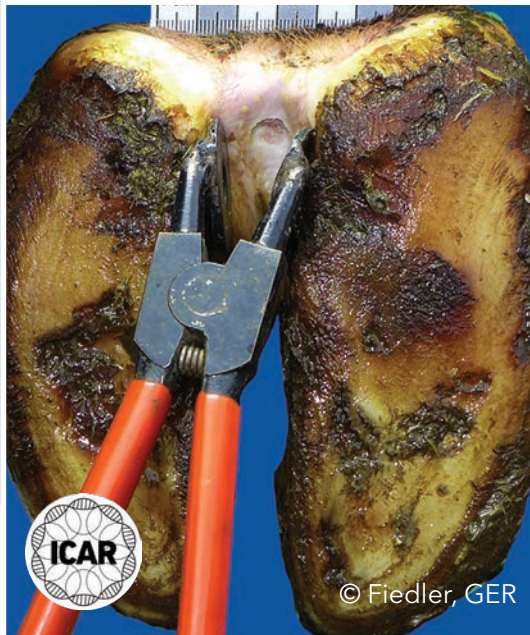# M0 stage

Normal, healthy skin with no visible signs of DD infection or other skin lesions.



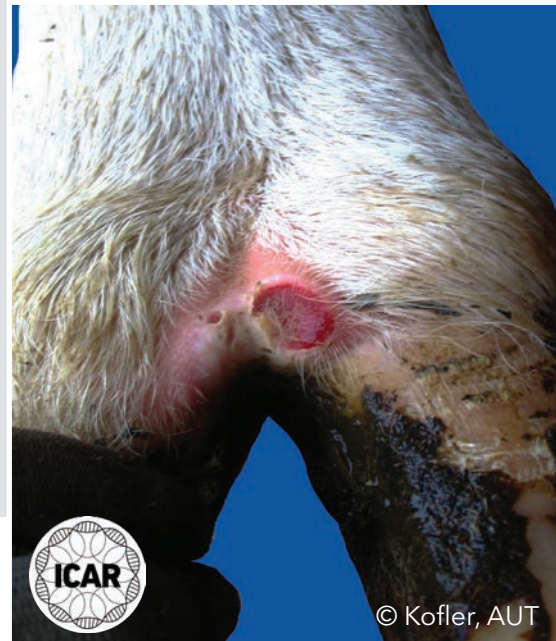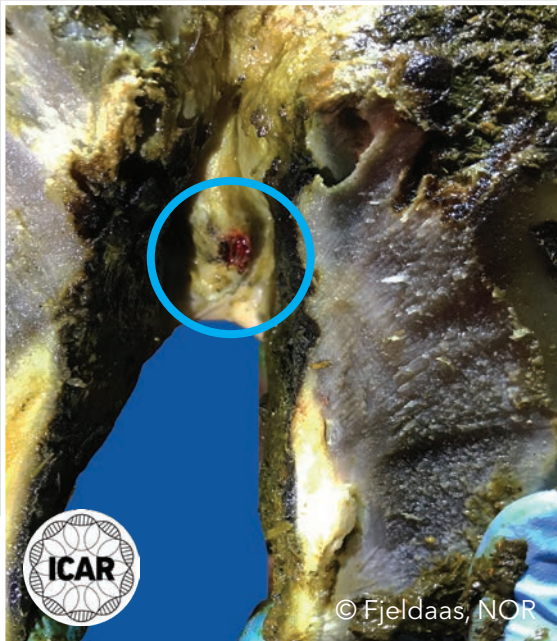
## M1 stage

Early-stage, small, focal active, red-grey circumscribed lesion less than 2 cm in diameter located on the skin of the plantar interdigital cleft (left) and on the skin of the interdigital cleft (right). The use of spreader forceps is shown to support the detection of M1 stages.



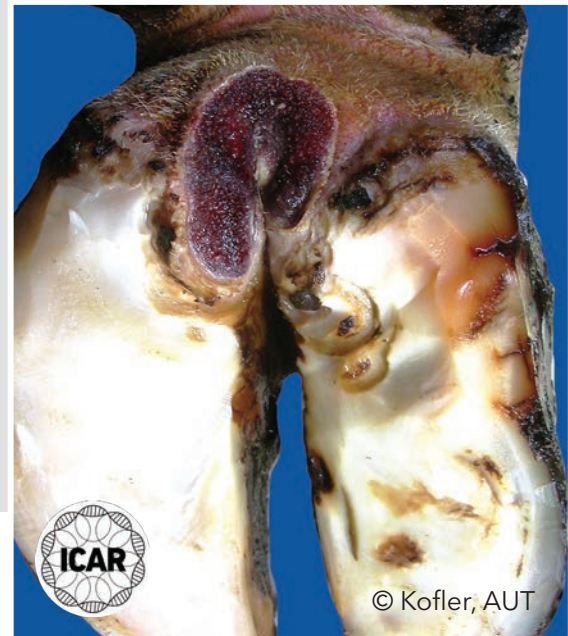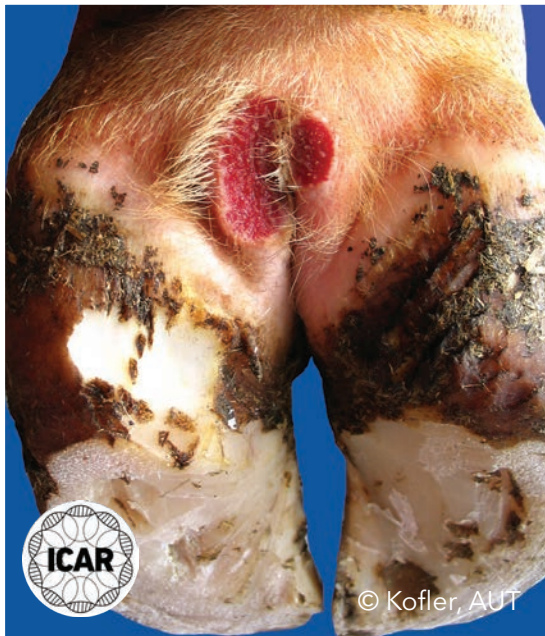# M1 stage

Early-stage, small, focal active, red-grey circumscribed lesion less than 2 cm in diameter located on the interdigital skin (left) and on the dorsal interdigital skin (right).



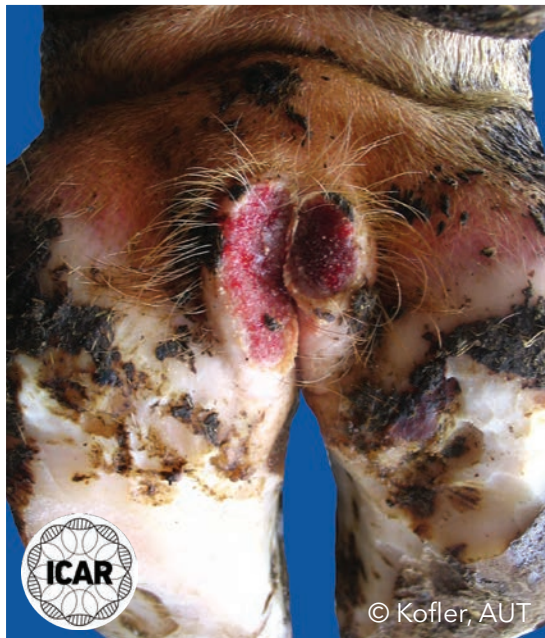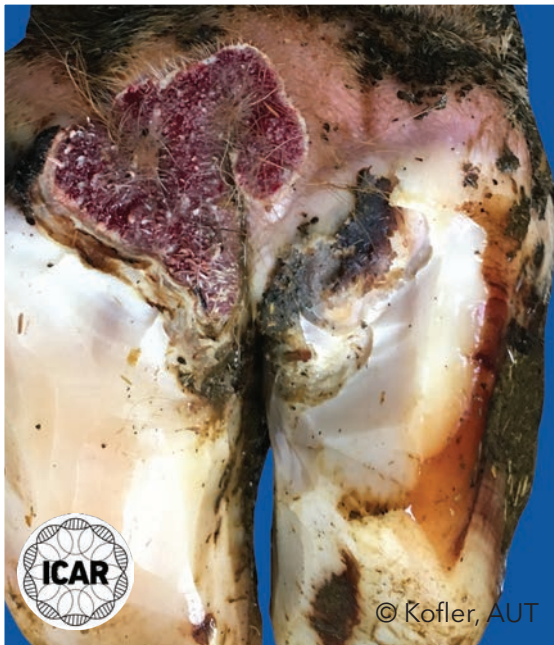
## M2 stage

Acute, bright red or red-gray ulcerative and painful lesion of a minimum of 2 cm in diameter located on the skin of the plantar interdigital cleft.



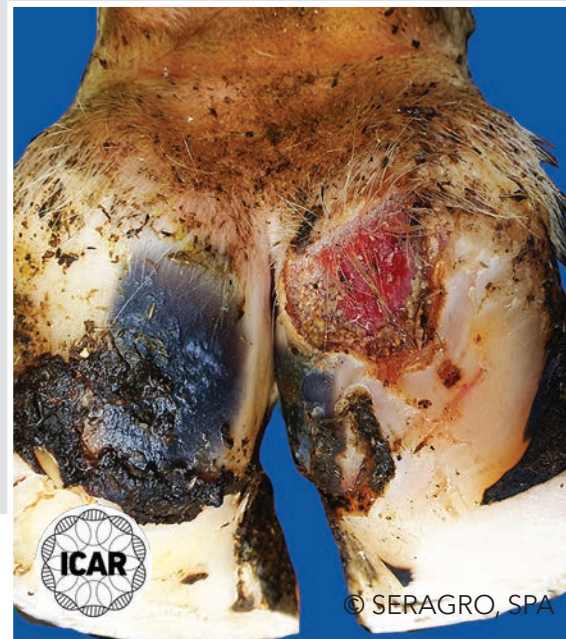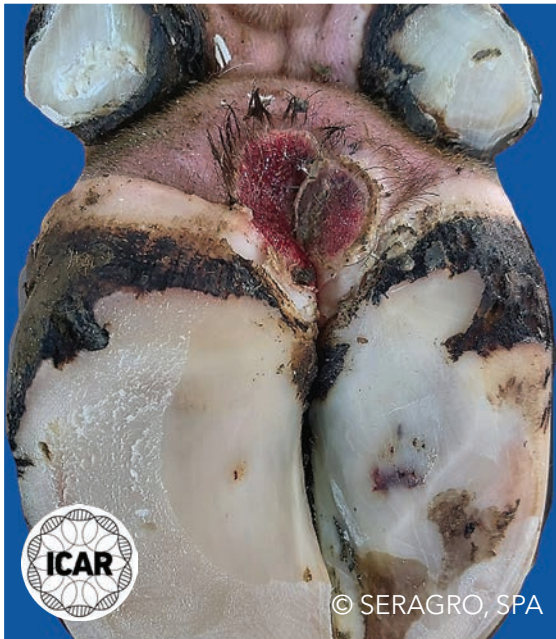
## M2 stage

Acute, bright red or red-gray ulcerative and painful lesion of a minimum of 2 cm in diameter located on the skin of the plantar interdigital cleft.



## M2 stage

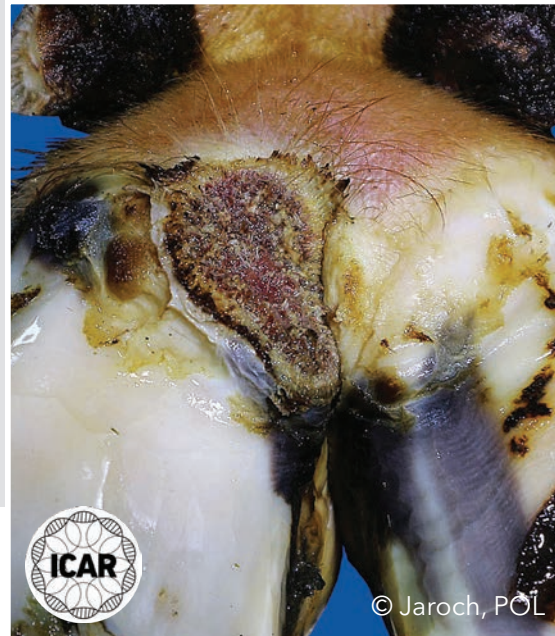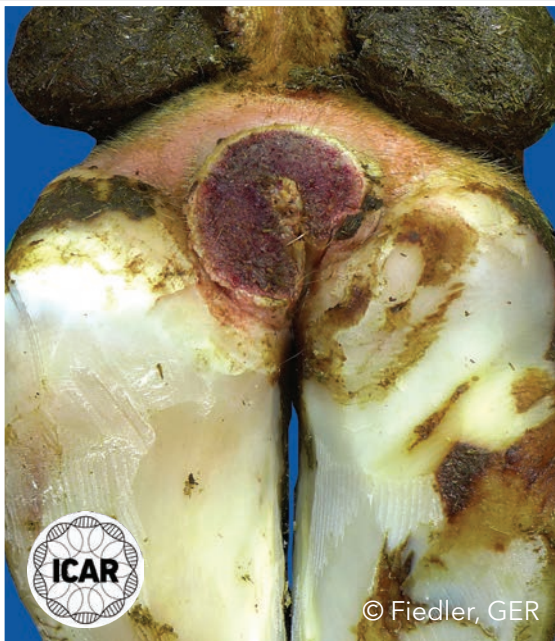Acute, bright red or red-gray ulcerative and painful lesion of a minimum of 2 cm in diameter located on the skin of the plantar interdigital cleft (left) and on the coronary band and the corium of the bulb of the heel (right).





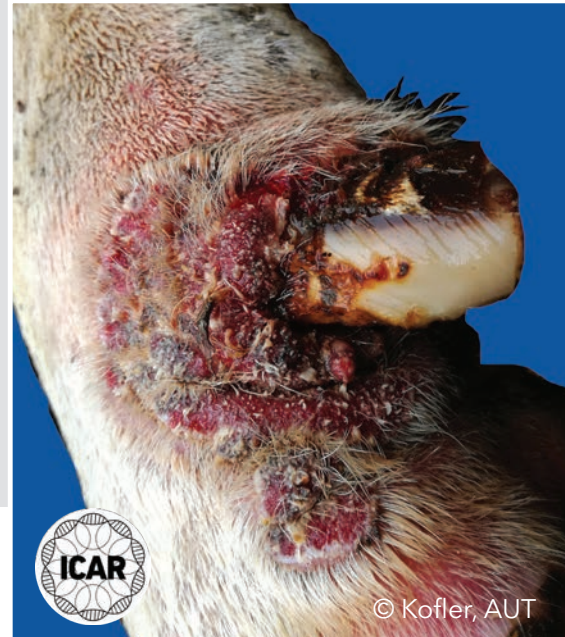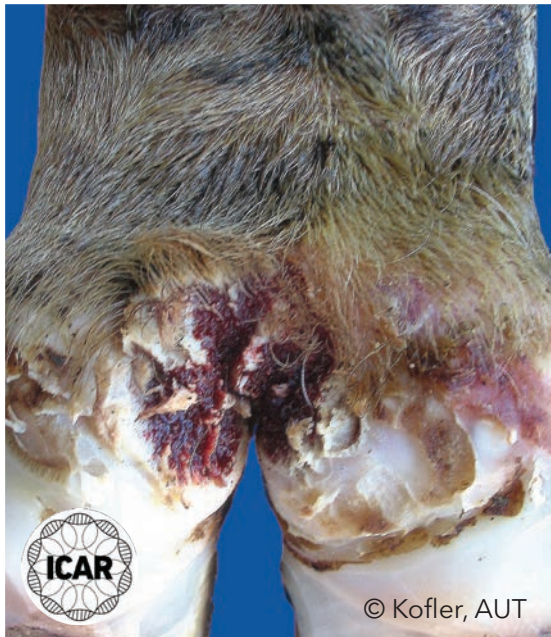## M2 stage

Acute, bright red or red-gray ulcerative and painful lesion a minimum of 2 cm in diameter located on the skin of the plantar interdigital cleft.



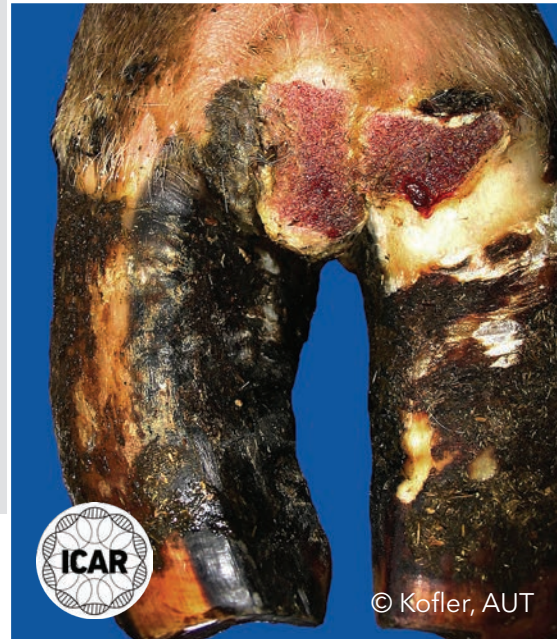## M2 stage

Acute, bright red or red-gray ulcerative and painful lesion of a minimum of 2 cm in diameter located on the skin of the plantar interdigital cleft (left) and around the dew claw (right).



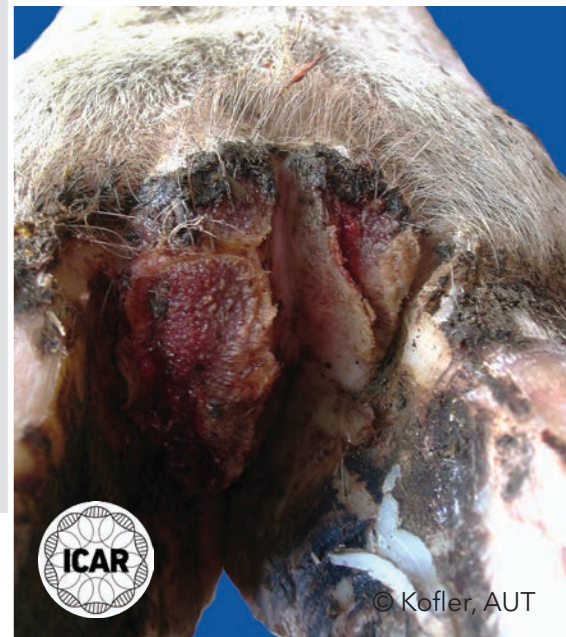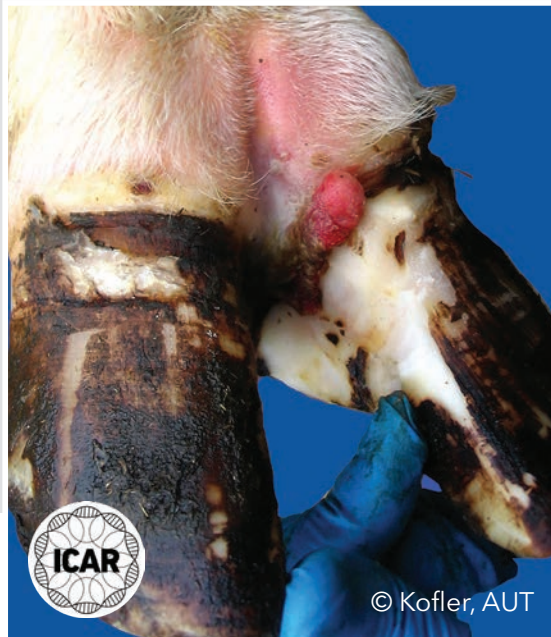## M2 stage

Acute, bright red or red-gray ulcerative and painful lesion of a minimum of 2 cm in diameter located on the skin of the dorsal interdigital cleft.



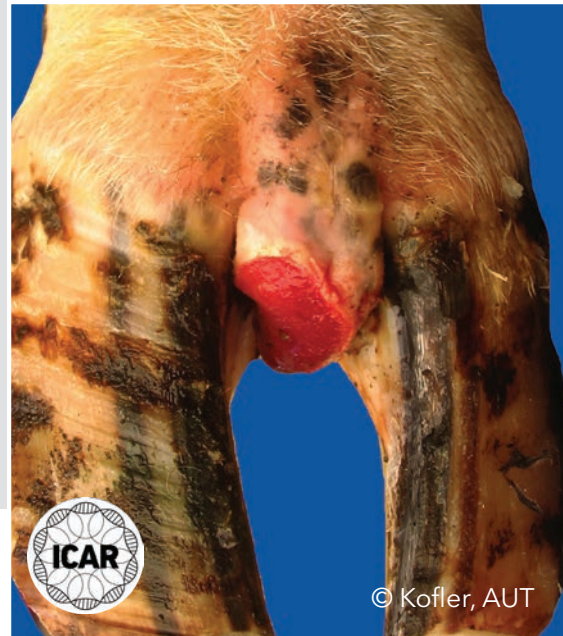
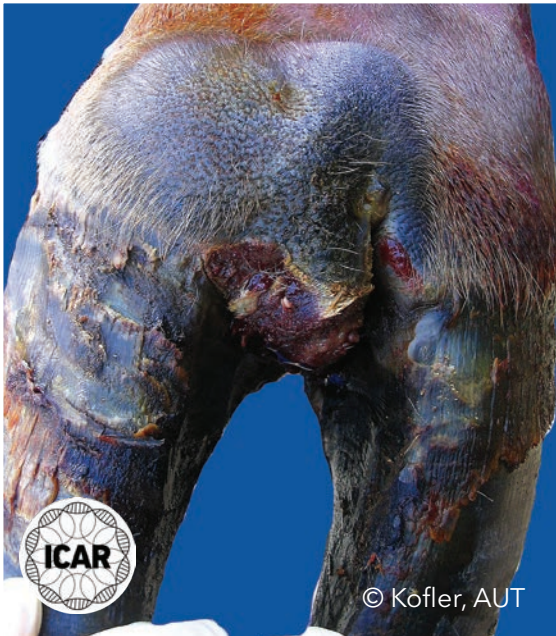
## M2 stage

Acute, bright red or red-gray ulcerative and painful lesion of a minimum of 2 cm in diameter located on the skin of the dorsal interdigital cleft involving the corium of the periople (left), and located on the interdigital skin with proliferative and hyperkeratotic growth (right).



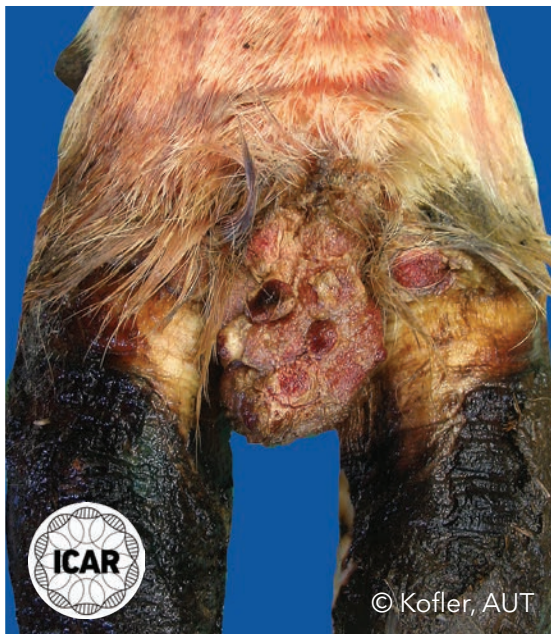
## M2 stage

Acute, bright red or red-gray ulcerative and painful lesion of a minimum of 2 cm in diameter located on the top of an interdigital hyperplasia.



## M2 stage

Acute, bright red or red-gray ulcerative and painful lesion of a minimum of 2 cm in diameter; numerous M2 lesions are located on the top of an interdigital hyperplasia.

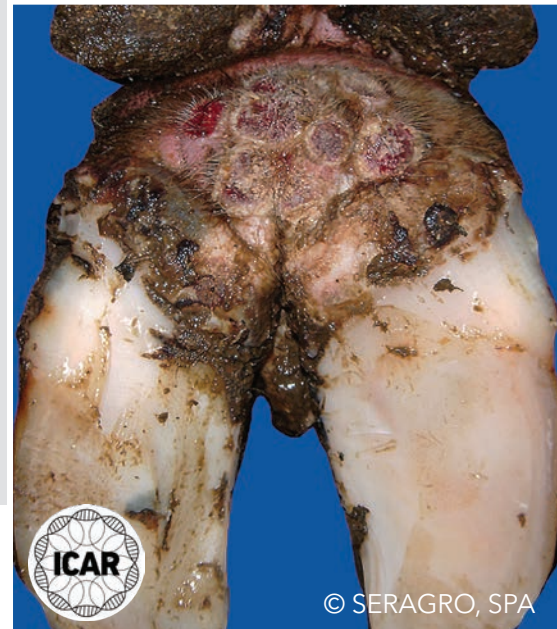
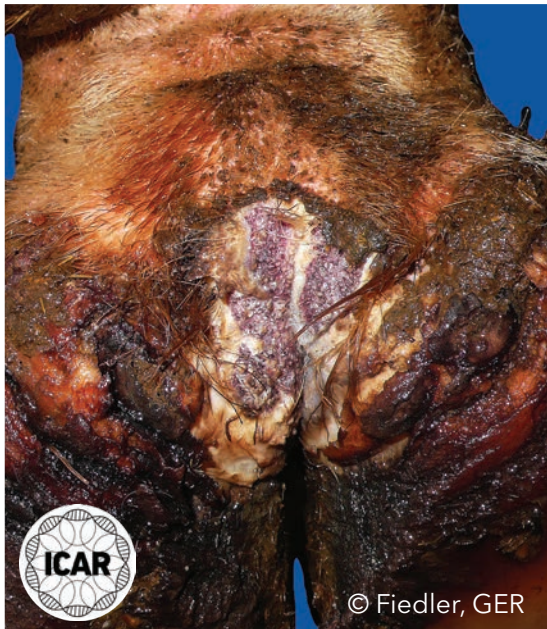
© Kofler, AUT



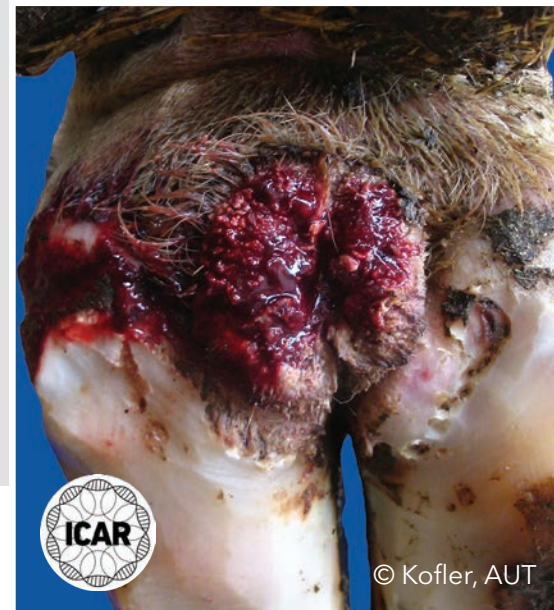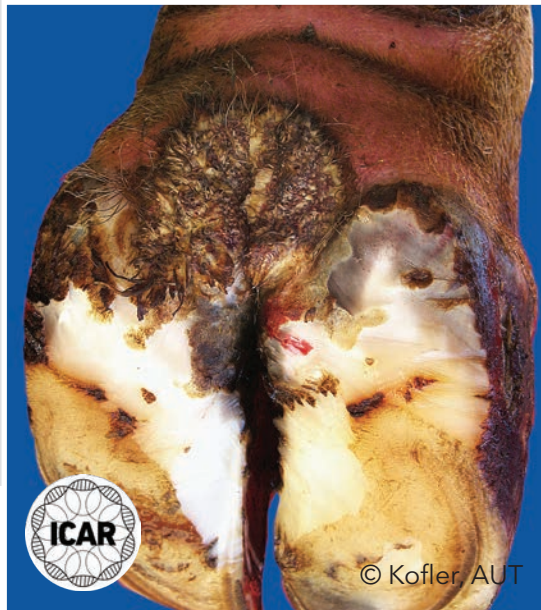
## M2 stage (proliferative)

Acute, bright red or red-gray ulcerative and painful lesion of a minimum of 2 cm in diameter; numerous M2 lesions are lying close together on the skin of the plantar interdigital cleft (left) and on the skin of almost the entire plantar pastern region (right).



## M2 stage (proliferative)

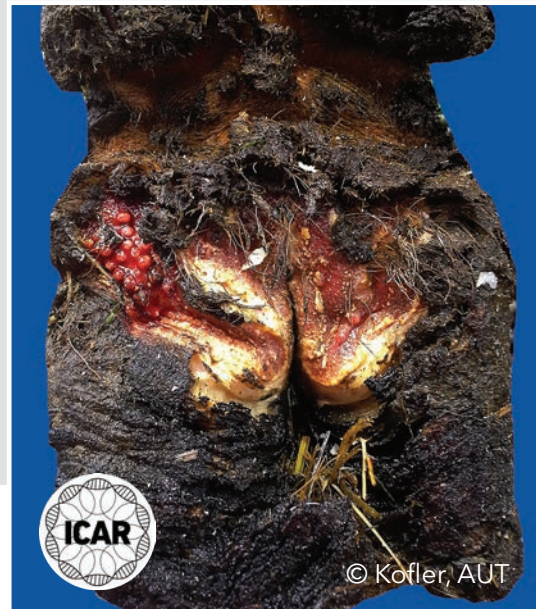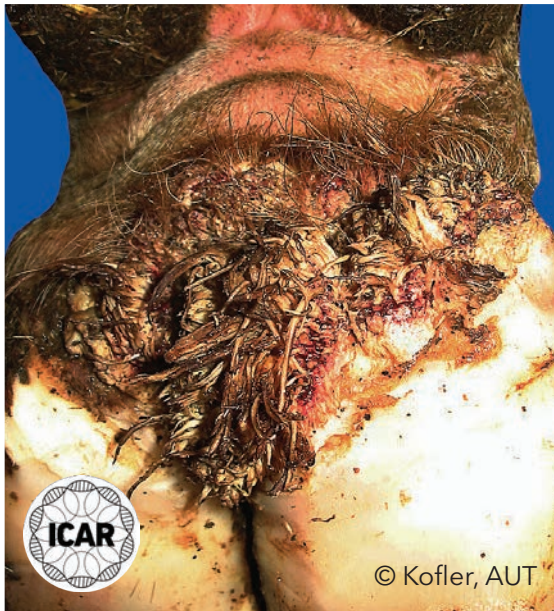Acute, bright red or red-gray ulcerative and painful lesion of a minimum of 2 cm in diameter located on the skin of the plantar interdigital cleft. There is an excessive hyperkeratotic epidermal growth in both these M2 lesions.





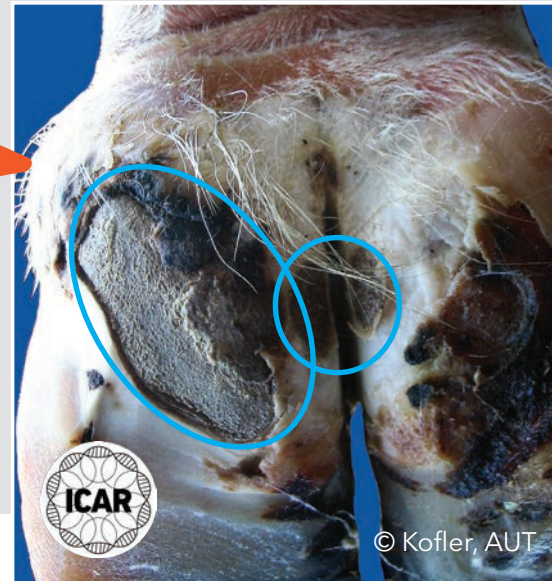
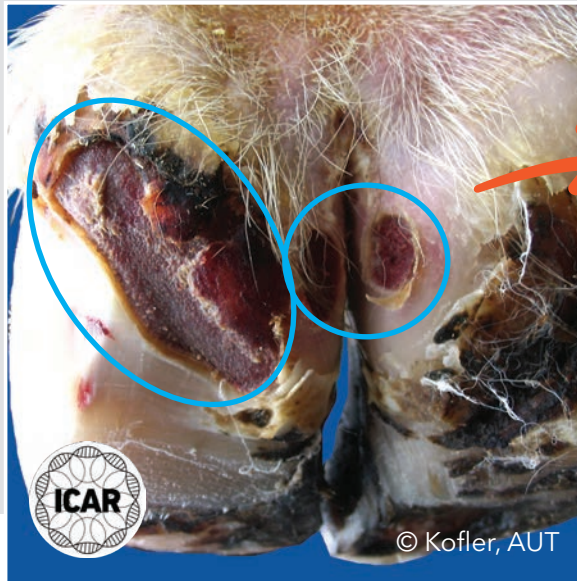
## M2 stage (proliferative)

Acute, bright red or red-gray ulcerative and painful lesion of a minimum of 2 cm in diameter located on the skin of the plantar interdigital cleft. There is an excessive hyperkeratotic proliferative epidermal growth (left) and a highly increased heel height (right), caused by the non-weight bearing of the plantar sole area for a prolonged period.



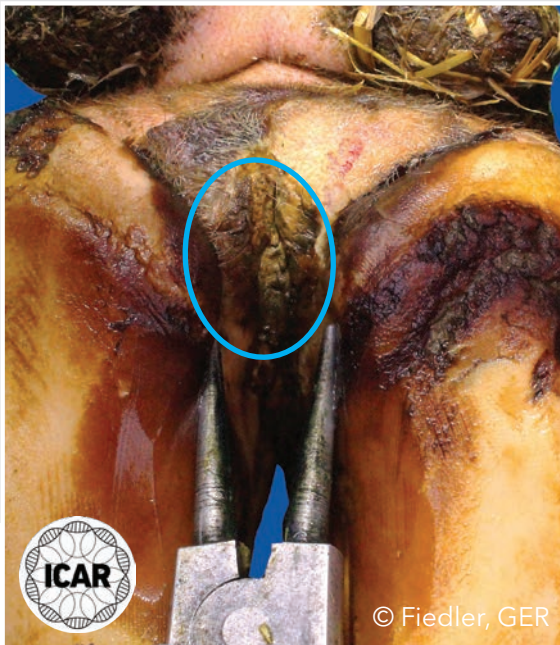
## M2 stage and transition into M3 stage

Numerous M2 stages are identifiable on the left figure. Five days after topical treatment using salicylic acid and a bandage, painless M3 lesions (right) are covered with firm gray scabs.



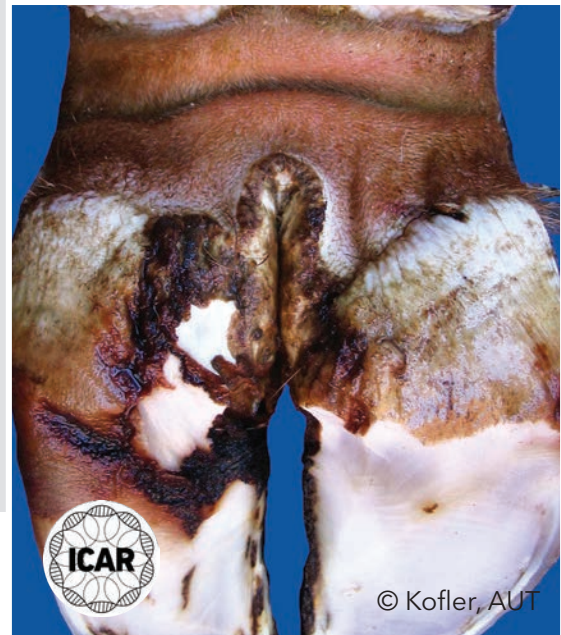
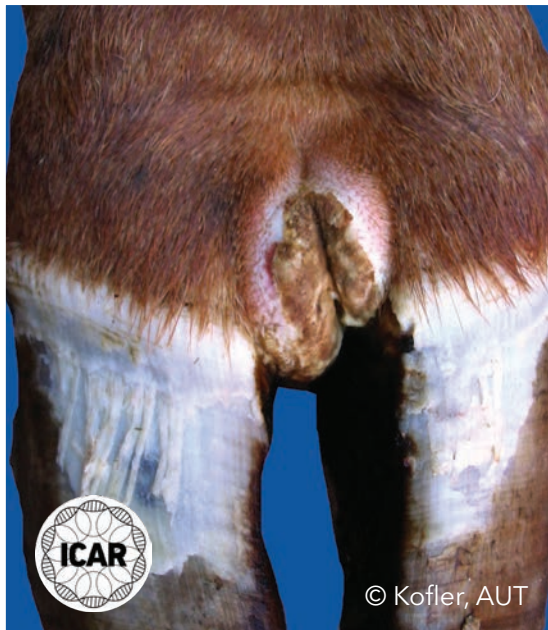
## M3 stage

Healing, painless M3 lesion seen after topical treatment covered with firm, brown/black scab material; the color of the scab depends on the topical medication applied.



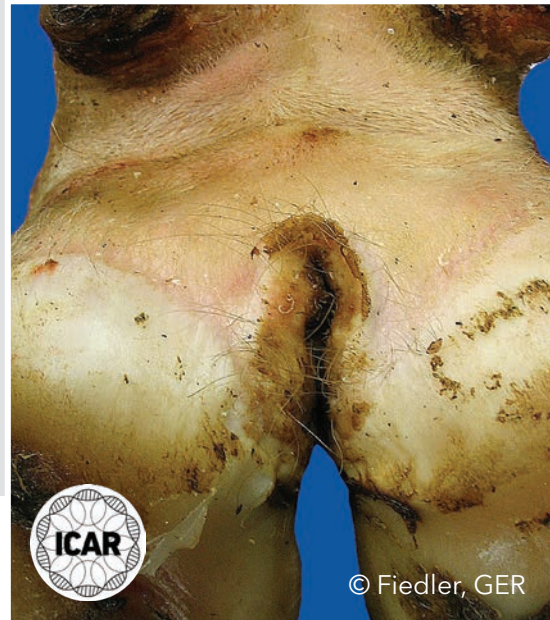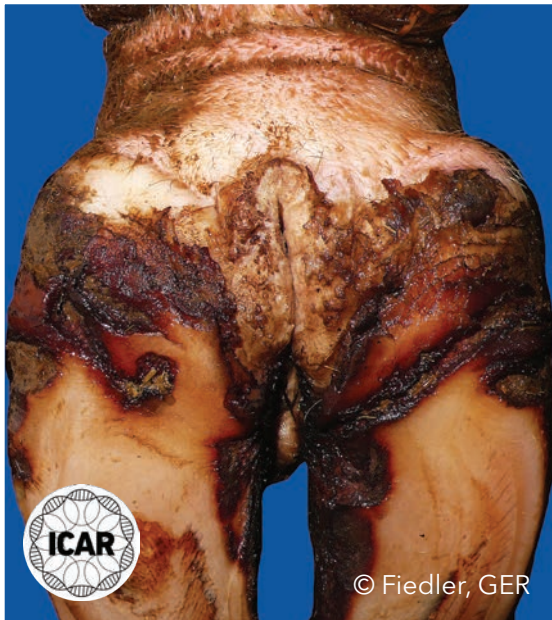## M4 stage

Chronic stage characterized by a non-painful, clearly circumscribed lesion of various sizes showing dys- and hyperkeratotic overgrowths ('wart-like') of brown-gray color. M4 stages may also be characterized by a scab-like mass or hyperkeratotic proliferations, such as here on the dorsal (left) and the plantar interdigital skin (right).



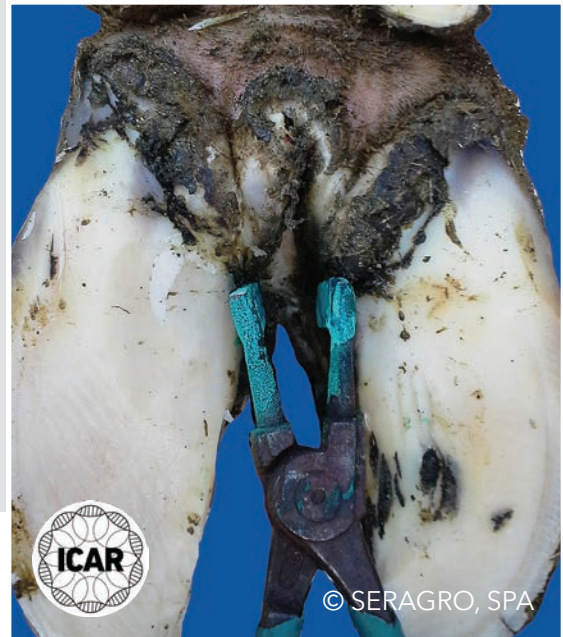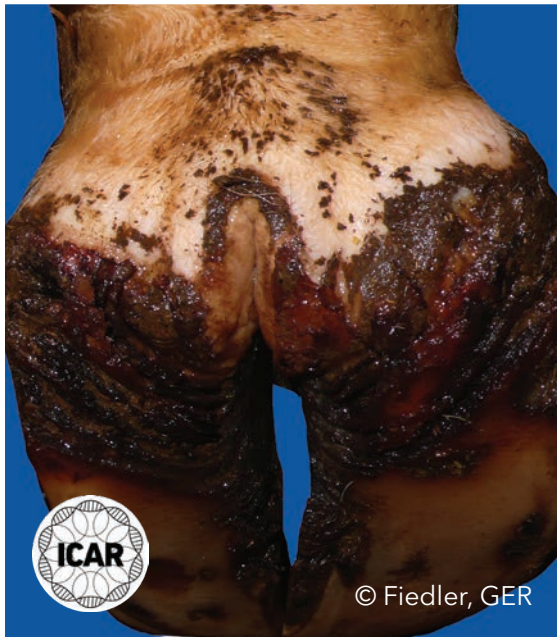
## M4 stage

Chronic stage characterized by a non-painful, clearly circumscribed lesion of various sizes showing dys- and hyperkeratotic overgrowths ('wart-like') of brown-gray color. M4 stages may also be characterized by a scab-like mass or hyperkeratotic proliferations on the plantar interdigital skin.



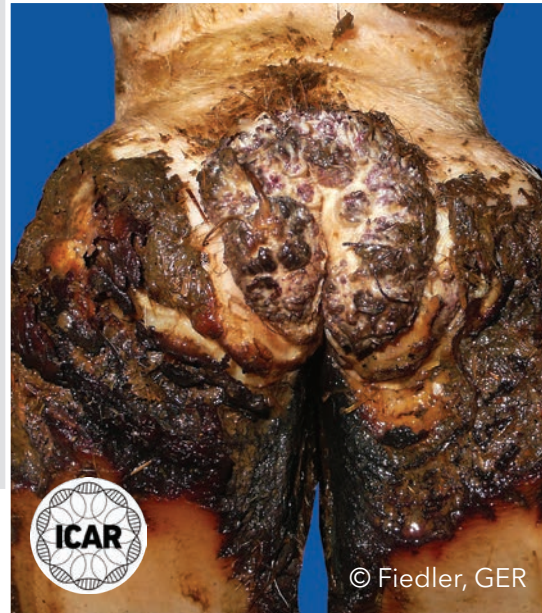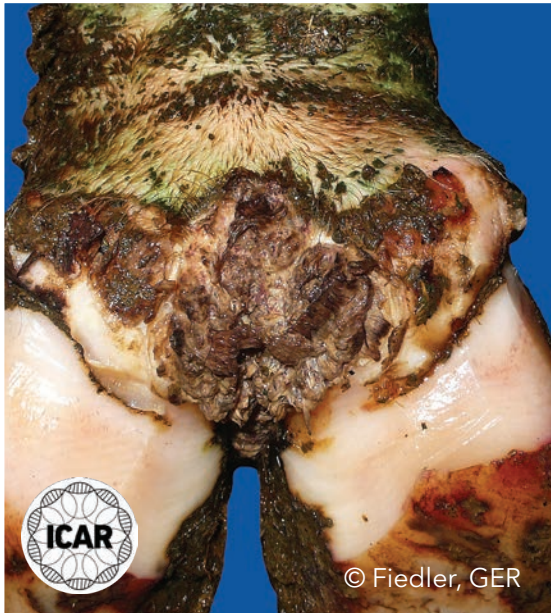## M4 stage

Chronic stage characterized by a non-painful, clearly circumscribed lesion of various sizes showing dys- and hyperkeratotic overgrowths ('wart-like') of brown-gray color. M4 stages may be characterized by a scab-like mass (in both images this is located on the plantar interdigital skin) or hyperkeratotic filamentous proliferations.



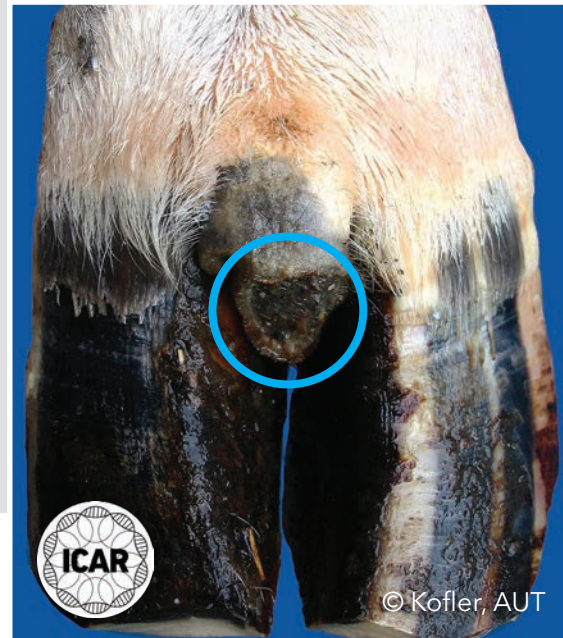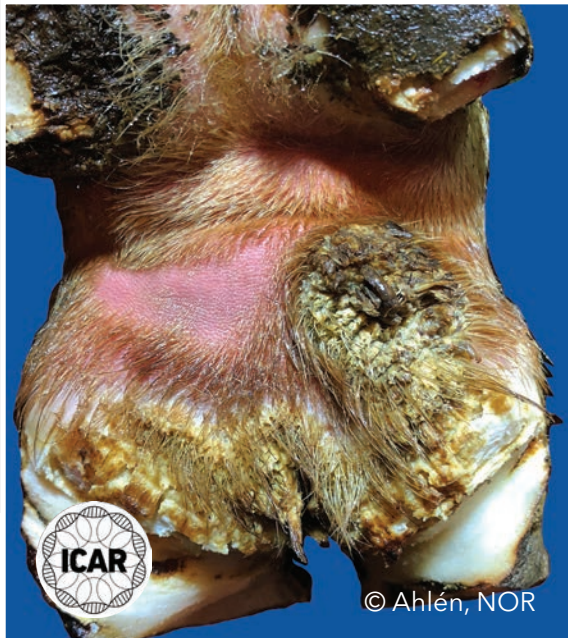## M4 stage

Chronic stage characterized by a non-painful, clearly circumscribed lesion of various sizes showing dys- and hyperkeratotic overgrowths ('wart-like') of brown-gray color. M4 stages may also be characterized by a scab-like mass or hyperkeratotic proliferations (shown in both images) on the plantar interdigital skin.



## M4 stage

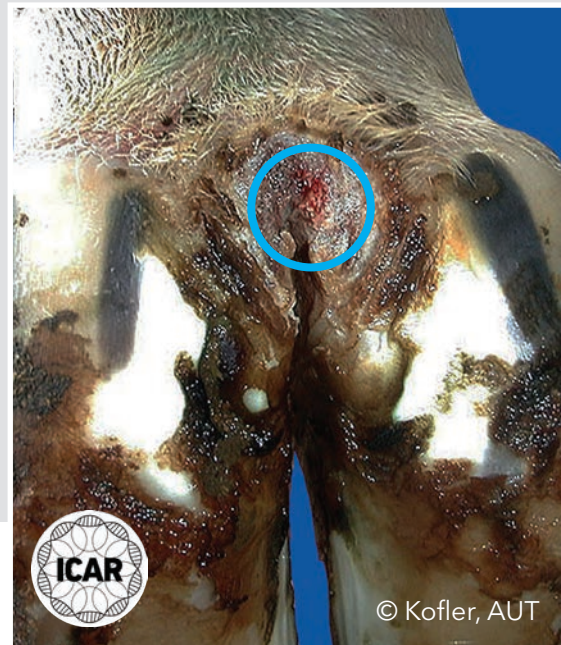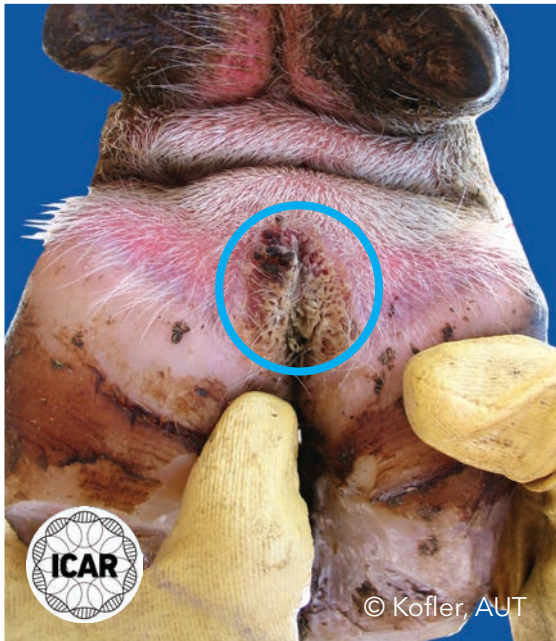Chronic stage characterized by a non-painful, clearly circumscribed lesion of various sizes showing dys- and hyperkeratotic overgrowths ('wart-like') of brown-gray color. M4 stages may be characterized by hyperkeratotic filamentous proliferations (left) or a scab-like mass located on the top of an interdigital hyperplasia (right).





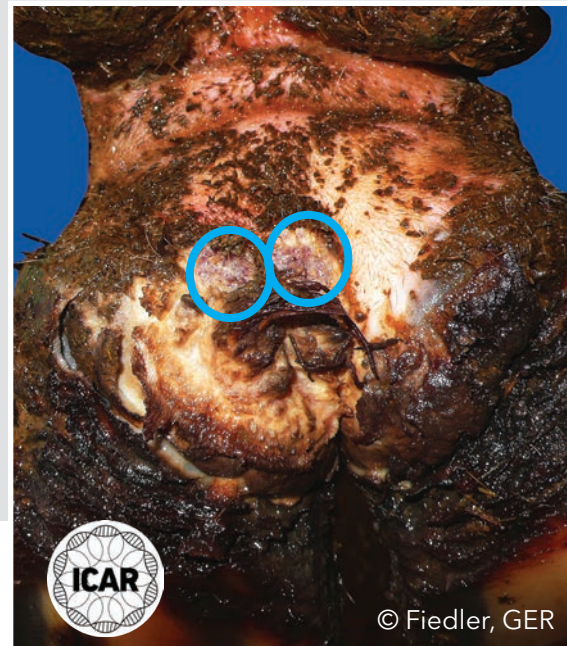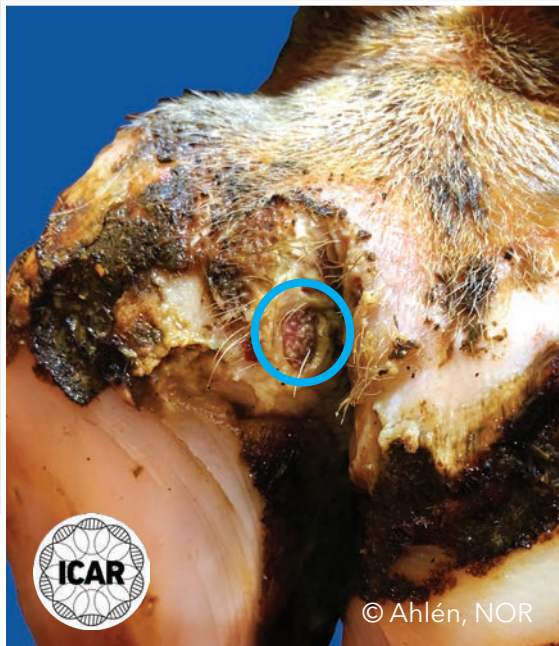## M4.1 stage

Chronic M4 stages showing a new red M1 lesion (circled) developing within the chronic hyper- and dyskeratotic M4 lesion on the plantar interdigital skin.



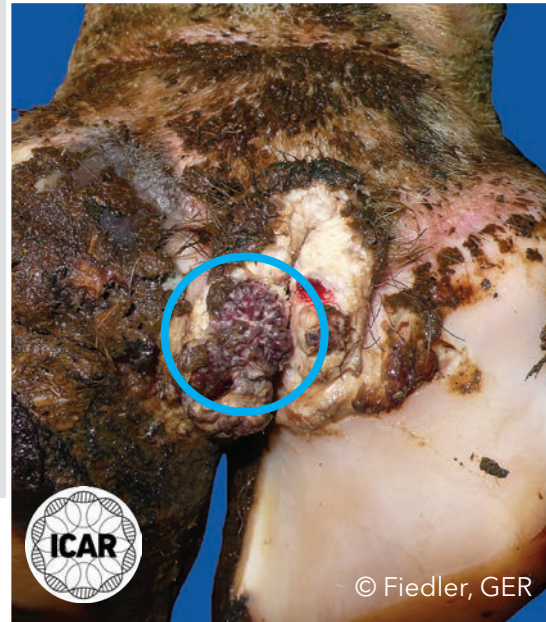
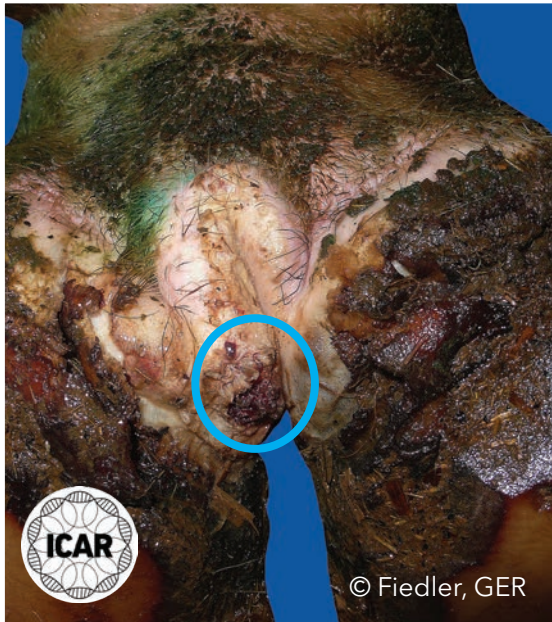## M4.1 stage

Chronic M4 stages showing a new red M1 lesion (circled) developing within the chronic hyper- and dyskeratotic M4 lesions on the plantar interdigital skin.



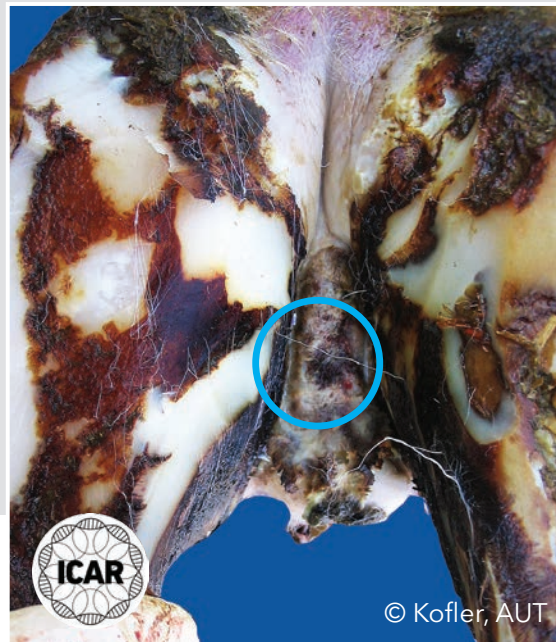
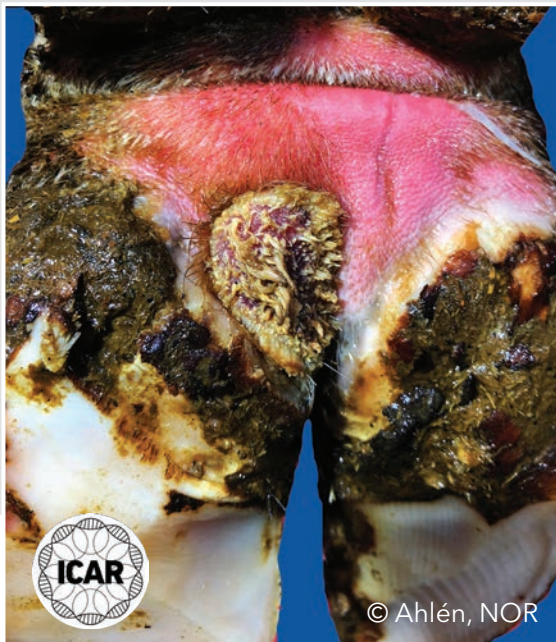## M4.1 stage

Chronic M4 stages showing a new red M1 lesion (circled) developing within the chronic hyper- and dyskeratotic M4 lesion located on the plantar interdigital skin.



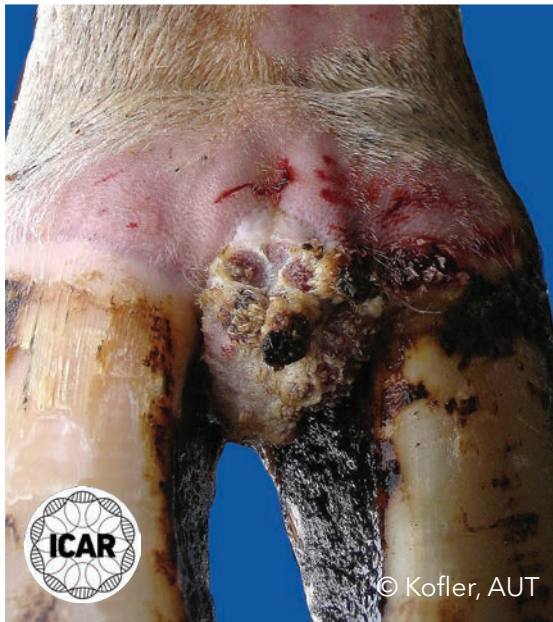## M4.1 stage

Chronic M4 stage showing a new M1 lesion developing within the chronic hyper- and dyskeratotic M4 lesion located on the plantar interdigital skin (left) and on the interdigital skin (right).



## M4.1 stage

Chronic M4 stage showing a new M1 lesion developing within the chronic hyper- and dyskeratotic M4 lesion; the image shows numerous M1 lesions located on the top of an interdigital hyperplasia.

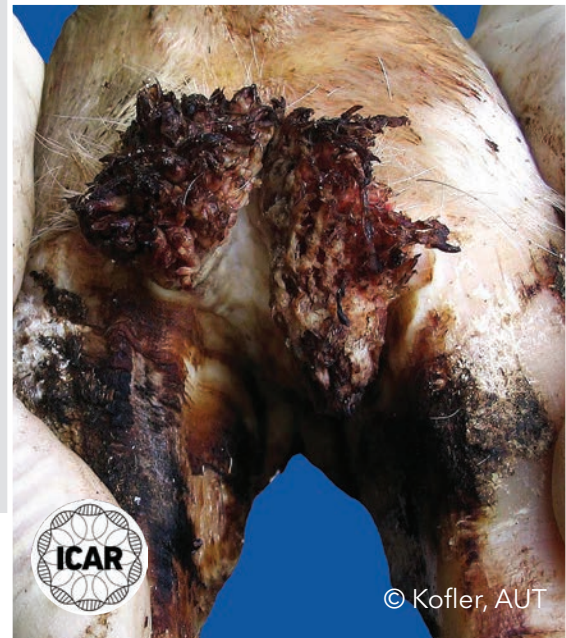
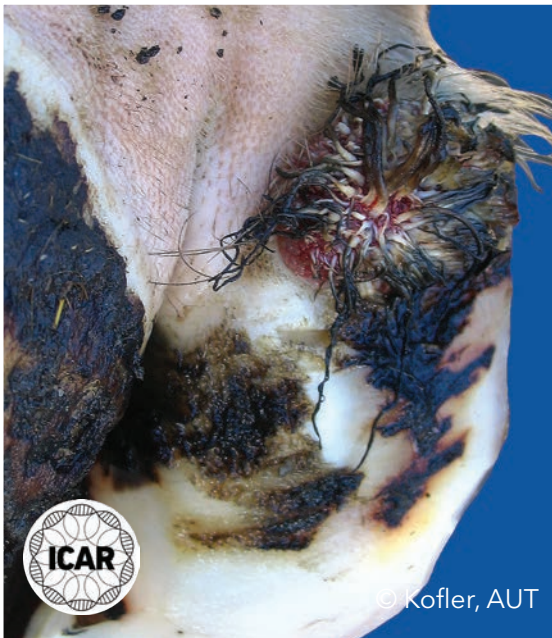
© Kofler, AUT



## M4.1 stage (proliferative)

Chronic M4 stage showing a new M1 lesion developing within the chronic hyper- and dyskeratotic M4 lesion. In addition to hyperkeratosis, an obvious and prominent proliferative/filamentous epidermal growth over the bulb of the heel (left) and on the dorsal interdigital skin (right) can be seen.



# List of image contributors

**Ahlén, Lina (NOR):** M4 P32a; M4.1 P34a; M4.1 P36a.

**Fiedler, Andrea (GER):** M0 P10a; M0 P11b; M1 P12a; M1 P12b; M2 P17a; M2 P23a; M3 P27a; M4 P29a; M4 P29b; M4 P30a; M4 P31a; M4 P31b; M4.1 P34b; M4.1 P35a; M4.1 P35b.

**Fjeldaas, Terje (NOR):** M1 P13a.

**Jaroch, Karol (POL):** M2 P17b.

**Kofler, Johann (AUT):** M0 P10b; M0 P11a; M1 P13b; M2 P14a; M2 P14b; M2 P15a; M2 P15b; M2 P18a; M2 P18b; M2 P19a; M2 P19b; M2 P20a; M2 P20b; M2 P21a; M2 P21b; M2 P22a; M2 P24a; M2 P24b; M2 P25a; M2 P25b; M2 transition into M3 P26a; M2 transition into M3 P26b; M4 P28a; M4 P28b; M4 P32b; M4.1 P33a; M4.1 P33b; M4.1 P36b; M4.1 P37a; M4.1 P38a; M4.1 P38b.

**SERAGRO Company (SPA):** M2 P16a; M2 P16b; M2 P23b; M4 P30b.

**Tiergesundheitsdienst (AUT):** Table of contents P4a; Table of contents P4b.

